

A version of the article in the Journal Oncology

Oncology News International

(September 1997 Volume 6 Number 9)

Infrared Imaging as a Useful Adjunct to Mammography

MONTREAL— A group of Canadian physicians hope to spark renewed interest in the use of infrared breast imaging as a complement to mammography.

This technology lost favor some 20 years ago, but with new ultra-sensitive high-resolution digital infrared devices, efficacy is much improved, and the Canadian researchers believe that infrared exams could prove a simpler and less expensive complement to mammography than some of the other newer imaging methods.

Researchers from the Ville Marie Breast Center examined infrared imaging in 100 women with non invasive stage I and II breast cancer. In this study, the 85% sensitivity rate of mammography alone was increased to 95% when infrared imaging was added, John R. Keyserlingk, MD, a surgical oncologist at Ville Marie, said in his presentation of the findings at the recent American Society of Clinical Oncology annual meeting.



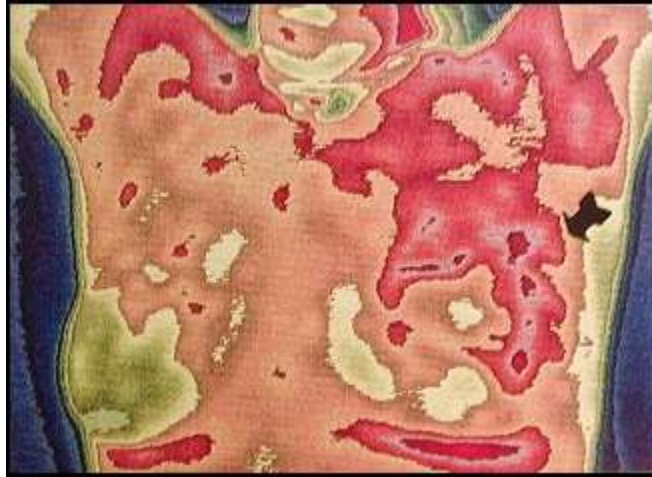In this 38 year-old woman with a lump in the upper mid part of the left breast, mammography showed bilaterally dense fibroglandular tissue, more prominent on the left side. Infrared imaging (above) shows an asymmetrical vascular pattern over the left breast. Histopathology revealed a 2-cm infiltrating ductal carcinoma of the left breast.

Mammography and ultrasound depend primarily on structural distinction and anatomical variation of the tumor from the surrounding breast tissue, Dr Keyserlingk said, Infrared imaging detects minute temperature variations related to vascular flow and can demonstrate abnormal vascular patterns associated with the initiation and progression of tumors.

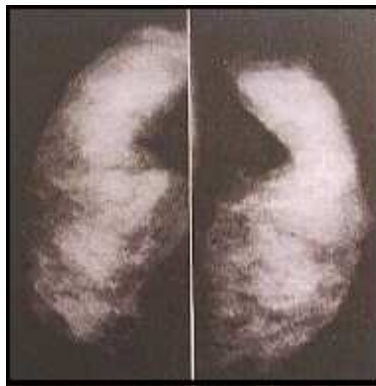
The new generation of diagnostic infrared technology, Dr. Keyserlingk said, owes much to a decade of military research and development. "In July 1995, we installed a fully integrated high-resolution infrared station," he told ONCOLOGY NEWS INTERNATIONAL. The software allows high - precision pixel temperature measurements.

In their study, Dr. Keyserlingk and his colleagues, Paul Ahlgren, MD, a medical oncologist, and Edward Yu, MD, a radiation oncologist, reviewed 100 successive patients referred to the Ville Marie Breast Center between August 1995 and December 1996 who were subsequently found to have histologically proven noninvasive ductal carcinoma in situ (four patients) or stage I or II invasive breast cancer (96 patients).

All patients had undergone preoperative clinical examination, mammography, and infrared imaging.



The infrared image from the same patient (see mammography below) shows a marked asymmetrical area of increased vascularity in the left breast (arrow). Histopathology revealed a 3-cm infiltrating ductal carcinoma of the left breast with 11 positive axillary nodes.



In this 39-year-old woman with a lump in the left breast, mammography (craniocaudal view) shows bilaterally dense fibroglandular tissue, more prominent on the left side.

Clinical examination alone was positive in 61% of the study patients. Mammography was highly suspicious in 66% of patients, with an additional 19% having contributory but nonspecific (intermediate) mammography findings. Infrared imaging was considered abnormal in 83% of patients.

Of the 39 patients with negative clinical examinations, 31 had at least one major abnormal infrared sign, and infrared was the major indication of a potential abnormality in 15 of these patients who also had a negative or intermediate mammogram.

The 15 patients with a noncontributory mammogram were an average of five years younger than the overall group (mean age, 48 years versus 53 years). Among these patients, 10 had an abnormal infrared image, and in six of these women, who also had negative clinical exams, infrared was the main indicator of a possible abnormality.

"This suggests that when done concomitantly with mammography, infrared imaging can add valuable information, particularly in those patients with nonspecific clinical and mammographic findings," Dr. Keyserlingk said.

The mean size of tumors undetected by mammography was 1.66 cm versus 1.28 cm for infrared imaging, suggesting that infrared detection is related more to vascular and metabolic changes than strictly to tumor size.

Finally, for comparison the researchers evaluated a series of 100 patients who had benign breast histology at open biopsy. Of these, 19% had an abnormal preoperative infrared study, while 30% had an abnormal mammogram, suggesting sufficient specificity as an adjuvant modality.

Dr. Keyserlingk noted that infrared imaging generally takes less than 10 minutes to perform. At the Ville Marie Breast Center, he said, patients are asked to avoid alcohol, coffee, smoking, exercise, deodorants, and lotions three hours before their infrared test.

The imaging room is maintained at between 18° and 20° C. The patient sits disrobed, hands supported over her head for a five-minute equilibration period. Imaging is then performed, consisting of four views - one anterior, one undersurface, and two lateral -which are taken, interpreted, and stored on laser disks in a process that takes only two minutes

Major abnormal findings on infrared range from significant vascular asymmetry to vascular "anarchy," consisting of unusual vessels that form clusters, loops and abnormal branching. Focal increases in temperature from 1° to 3° C may be significant when compared with temperatures at the contralateral site.

Dr Keyserlingk and his colleagues hope that their finding's will stimulate interest in infrared imaging and ultimately lead to carefully controlled multi-center trials of the technique.

Time to Reassess Value of Breast Imaging?